

# From guidelines to real daily practice: prolactinoma in pregnancy

L. Vroonen<sup>\*a</sup> (Dr), I. Potorac<sup>a</sup> (Dr), S. D'Andrea<sup>b</sup> (Dr), A. Beckers<sup>a</sup> (Pr)  
<sup>a</sup> CHU de Liège, Liège, BELGIQUE ; <sup>b</sup> Ospedale Universitario dell'Aquila,  
 L'Aquila, ITALIE

## INTRODUCTION

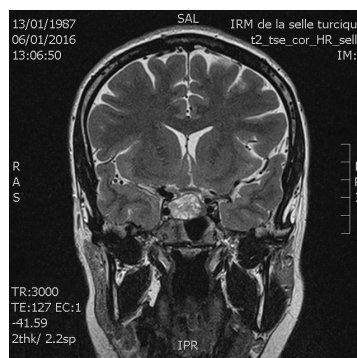
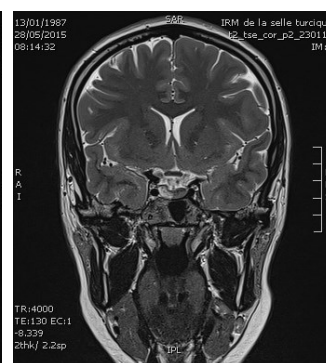
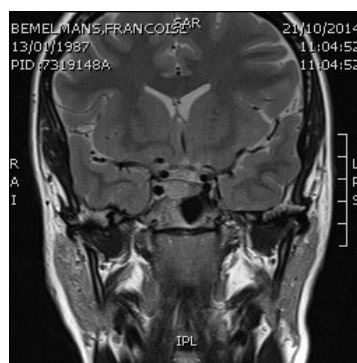
Prolactinoma is a frequent cause of hypogonadism. Dopamine agonist treatment is usually safe and efficient to restore fertility. During pregnancy, prolactinoma behavior depends on its initial size and its management can be challenging. In consequence, follow-up should be intensified in pregnant women.

## OBSERVATION

We report here the case of a 28 year old women, treated for symptomatic macroprolactinoma (adenoma size: 11mm(figure)-PRL: 429mg/L). Cabergoline treatment (0,5mg/week) allows a rapid clinical and radiological response (size: 5mm-PRL: 2,1mg/L), leading to regular menses. Cabergoline treatment was stopped on july 2015 because of a pregnancy. After 4 months, she reports galactorrhea. At that time, PRL levels raised up to 827mg/L and MRI revealed a tumor growth (size: 18mm). Low dose cabergoline treatment (dose: 0,25mg/week) was then reintroduced but did not control PRL levels (1226mg/L). Treatment was then intensified (dose:0,5mg/week) and led to a better control of PRL levels (247mg/L) and tumor size (11mm).

## CONCLUSION

Estrogen levels can influence lactotroph cells replication and prolactinoma size. Tumor growth of prolactinoma during pregnancy depends on their size (4,8% in treated macroprolactinomas-2,7% in treated microprolactinomas-22,9% in untreated macroprolactinomas). On the other hand, dopamine agonists are usually discontinued during pregnancy, although evidences about cabergoline and bromocriptine safety are growing. As PRL levels rise physiologically during pregnancy, management of prolactinoma in this situation can be challenging. In our case, a rapid elevation of PRL levels suggests a tumor growth. We therefore recommend a monthly evaluation in macroprolactinoma, even if initial response to dopamine agonist was positive.



|                               |                            |
|-------------------------------|----------------------------|
| Fig 1:<br>diagnosis           | Fig 2:<br>Pre<br>pregnancy |
| Fig 3:<br>during<br>pregnancy |                            |