

Ectopic prolactinomas and somatotropinomas

F. Chentli^a, K. Faraoun^b, S. Khider^c, F. Kessaci^d, D. Meskine^e

^a Faculté de médecine d'Alger, Service d'Endocrinologie et Maladies Métaboliques, CHU Bab El Oued., Alger, Algérie ;

^b Faculté de médecine d'Oran ,Service d'Endocrinologie et diabétologie, Oran

^c Faculté de médecine d'Alger, Service de Neurochirurgie, Hôpital Salim Zemirli, Alger,

^d Faculté de médecine d'Alger, Service de radiologie, Hôpital universitaire de Bab El Oued, Alger;

^e Faculté de médecine d'Alger, Service d'Endocrinologie et Métabolisme, hôpital Bologhine, Alger

INTRODUCTION: Ectopic pituitary tumors (EPT) are very rare comparing to eutopic ones. Their mechanism is still debated. Our aim was to report 10 cases observed in our practice.

CASES SERIE: 6 prolactinomas and 4 somatotroph adenomas were recorded. Their localization is as follows:

Localization	Prolactinomas	somatotroph adenomas	Total
Suprasellar	2	1	3
Sphenoid sinus	2	2	4
Clivus	2	1	3
TOTAL	6	4	10

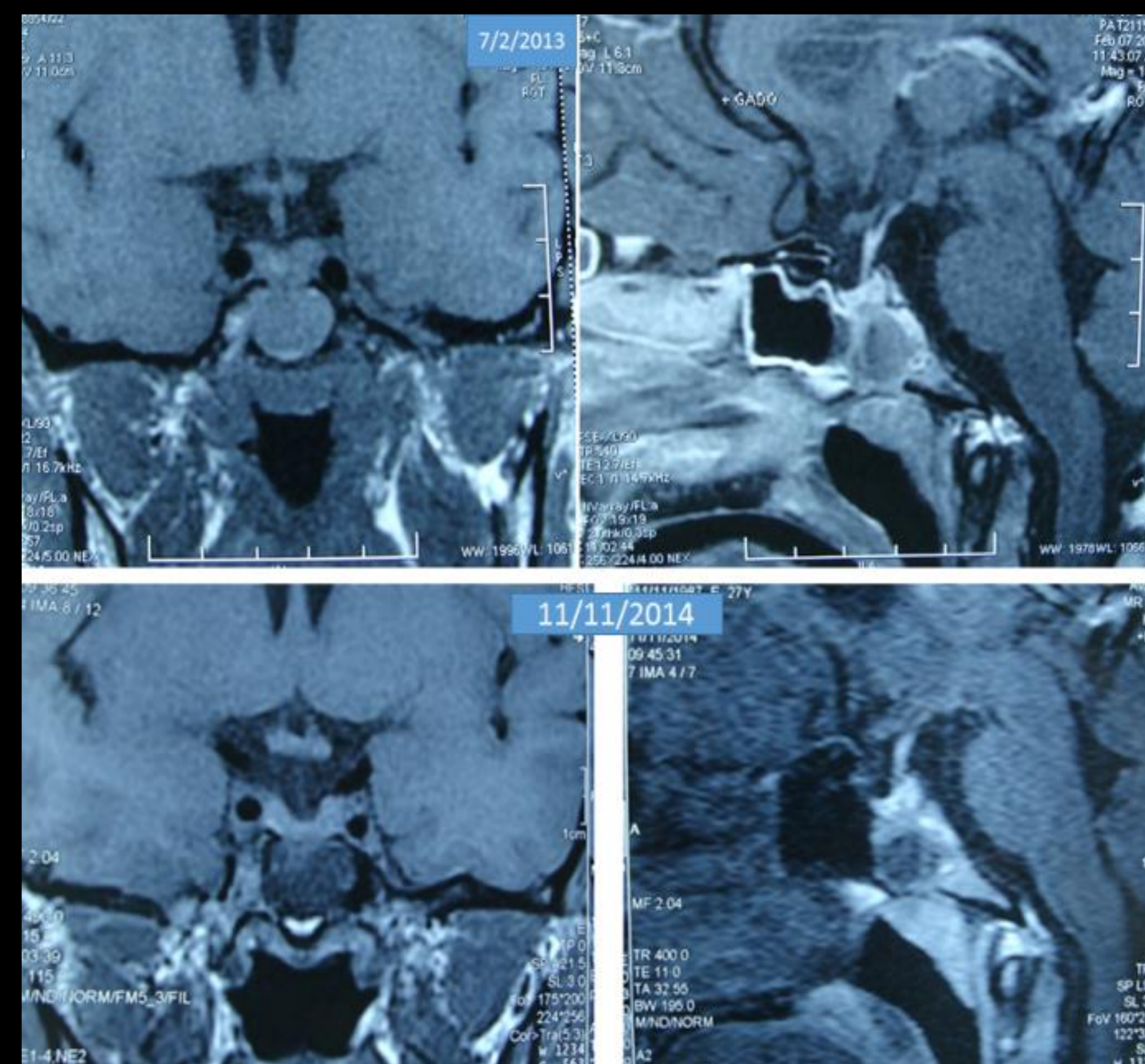


Fig 1: Clival prolactinoma before and after cabergoline.

Age at diagnosis =15-75ans, 2 males and 8 females. All were macro adenomas, symptomatic, and with a pure secretion.

❖ For the infrasellar lesions, the diagnosis was easy as the tumors were visible in the sphenoid sinus (Fig2) or in the clivus (Fig1). They all were associated to an empty sella suggesting an inhibition of the pituitary gland by an ectopic hormonal secretion.

❖ Regarding suprasellar lesions, the 3 tumors invaded the pituitary area without cavernous system invasion. The diagnosis was made in retrospect after tumor shrinkage under medical treatment. Actually, MRI done after medication showed a disappearance of the intrasellar part of the tumor first, and then it was the suprasellar part turn. After the last control, only a very small residual tumor was visible in the suprasellar area as in fig 3.

❖ On the therapeutic point, we remarked that inhibition of prolactin and growth hormone secretion was similar in both positions; however tumor shrinkage was better in suprasellar tumors.

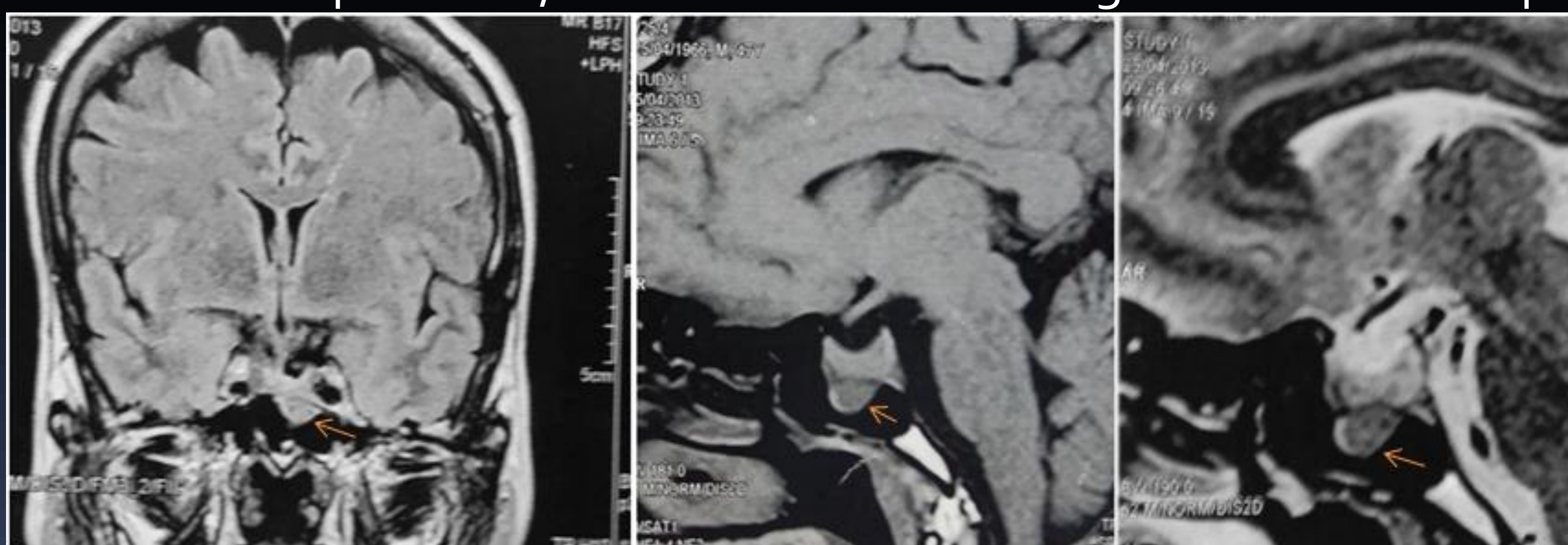


Fig2: somatotroph adenoma in the sphenoid sinus

Conclusion: Those 10 unusual cases should be known for their rarity, their unknown physiopathology and their response to medical treatment.

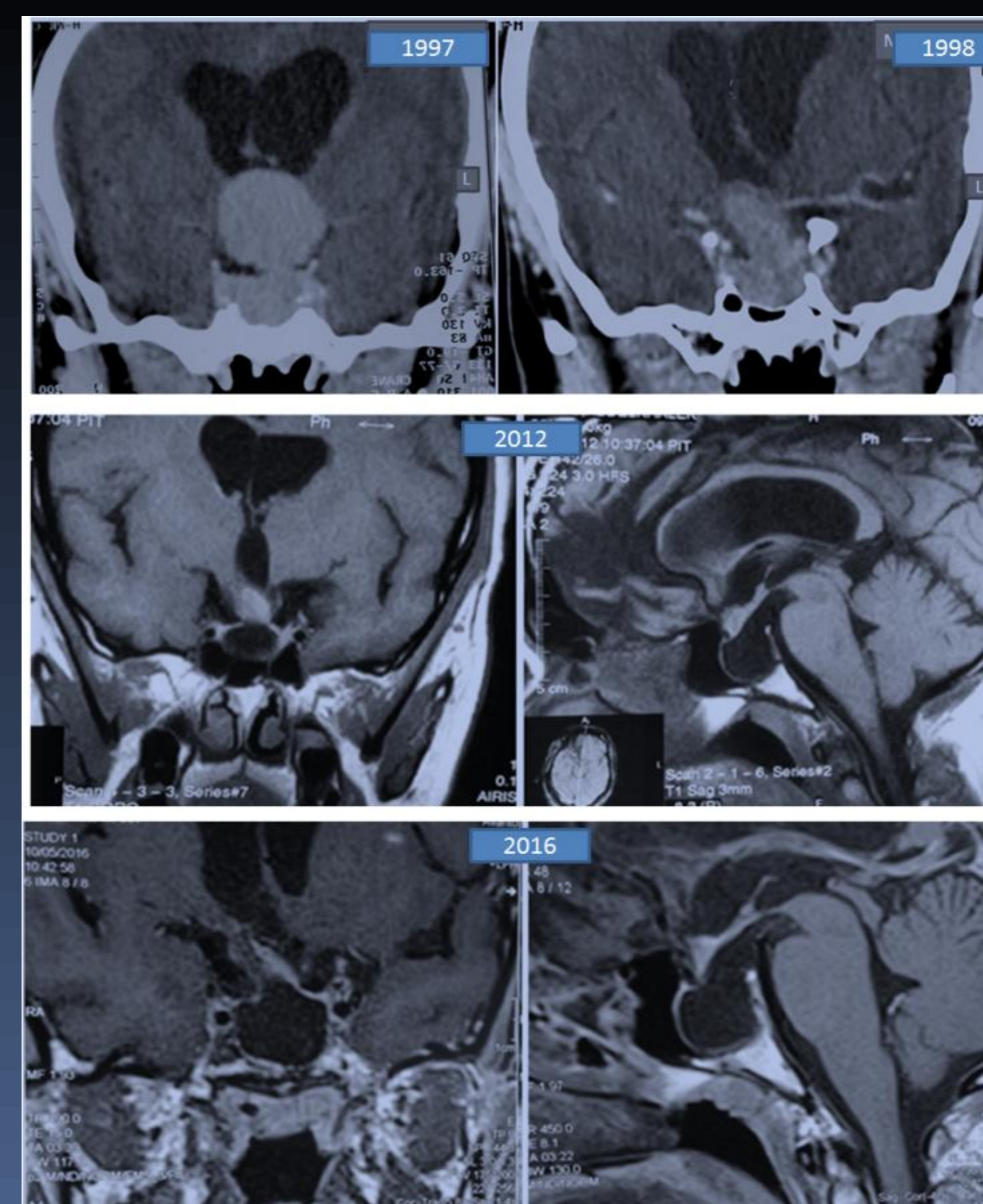


Fig3: Supra sellar Prolactinomas after medical treatment